RENEWING OF RAVITCH APPROACH FOR REPAIR OF PECTUS EXCAVATUM DEFORMITY: SURGICAL AND ANESTHETIC IMPLICATIONS

Waheed G. Etman MD,* Nader A. Faseh MD, Hossam Eldin F. Rida MD*****

Departments of Cardiothoracic surgery, Pediatrics** and Anesthesia and surgical intensive care*** Faculty of medicine, Alexandria University.*

ABSTRACT

Background: *Pectus excavatum is the most common chest wall deformity referred for surgical correction. As a congenital lesion, it is a highly visible anomaly and is easily diagnosed. Its anatomic severity can be readily assessed by visual measurement. Repair is undertaken to alleviate symptoms of pain, cardiac or respiratory compromise, as well as to diminish significant psychosocial consequences to a child or adolescent.*

Aim: *Was to study results of renewing the standard surgical approach to the pectus repair based on the technique described by Ravitch. Several technical modifications in the operative procedure and perioperative management strategy were added. Two post-operative pain management techniques were used following the Ravitch repair of pectus excavatum: continuous intravenous opioid analgesia, and thoracic epidural analgesia using opioid and local anesthetic combination.*

Methods: *This study included 15 patients (nine females 60% and six males 40%), their ages ranged from 8-13 years old with a mean of 10.6±2.7 subjected to pectus excavatum repair in the cardio-thoracic surgery department between 2001 and 2006. A limited transverse submamary skin incision with generous subcutaneous flap over the muscle fascia. Three to four sets of costal cartilages were removed to get optimal remodeling. The xiphoid process was detached from the sternum. An anterior wedge osteotomy was done using the redo sternal saw leaving the posterior table intact. Final stabilization was done using Kirshner wires mounted on drill, passing transversely under the lower segment of the sternum. Asymmetry can be easily dealt with by adjusting the angle of the osteotomy.*

Thoracic epidural catheter was routinely placed preoperatively by the anesthesiologist at the most appropriate level between T3 and T8, after induction of general anesthesia.

Results: *No operative mortality or significant intra-operative morbidities were reported. Blood loss was minimal. Two children developed ileus. One patient had a wound infection that required incision and drainage. Seromas developed after discharge in two patients. All patients had extubated before leaving the operating room and were sent to the thoracic surgery ward after leaving the recovery room. Both regimens provided effective analgesia.*

Conclusions: *A low morbidity with excellent short- and long-term results combined with a high level of patient satisfaction were achieved and should be the standard against which the Nuss procedure is compared.*

Indwelling epidural catheters placed at the time of surgery lead to smooth postoperative course. This strategy has greatly reduced the amount of narcotics required and allowed for more rapid mobilization.

Key Words: *Pectux excavatum, Ravitch repair, Nuss repair, thoracic epidural analgesia*

INTRODUCTION

Surgery of pectus deformity is challenging because self-image is a major concern in many patients. The leading pathology of pectus deformity is overgrowth of the costal cartilage that displaces the sternum either dorsally or ventrally. This results into deformity, which might be pectus excavatum or pectus carinatum. Such deformity (Fig 1) is common in the pediatric age group. The deformity appears initially or becomes more prominent during growth spurts.[1]

Repair is undertaken to alleviate symptoms of pain, cardiac or respiratory compromise, as well as to diminish significant psychosocial consequences to a child or adolescent.[1,2] For the last half century the standard surgical approach to the pectus repair has been based on the techniques described by Ravitch.[3] The basic principles include subperichondrial removal of the offending costal cartilage, remodeling of the sternum, and stabilization. Several reports have documented the results of the Ravitch approach.[4,5]

Recently, Nuss procedure; a two-stage, minimally invasive approach, has been advocated avoiding cartilage resection. As this technique is a relatively new technique, it is still in evolution.[6] Technical modifications have been made to minimize some of the reported complications including cardiac perforation and loss of bar position.

The post-operative pain management techniques used following the Ravitch repair of pectus excavatum were continuous intravenous opioid analgesia (CIOA), and thoracic epidural analgesia (TEA) using opioid and local anesthetic combination.[7] The benefits of CIOA versus TEA are unproven in adolescents.[8]

In our institution we have continued to use the Ravitch approach and several technical modifications in the operative procedure and perioperative management strategy were added. A retrospective chart review was performed to compare the pain outcome between these two pain management techniques to determine whether continuous thoracic epidural analgesia (TEA) after repair of pectus excavatum deformity is a viable and safe alternative to continuous intravenous opioid analgesia (CIOA) in children.

ISSN 1110-0834

METHODS

After approval by Alexandria Faculty of Medicine Research Ethics Committee, medical charts of 15 patients who underwent pectus excavatum repair in the cardio-thoracic surgery department between 2001 and 2006, were reviewed.

Operative and clinical data were reviewed for all patients including the severity grading of the deformity. The severity scale published by Davis and Weinstein was followed. It depends on numerical expression of one observer's subjective impression of severity supposing that 1 being barely noticeable and 10 being the most severe.[9] Preoperative computed tomography (CT) scanning was not used as a routine evaluation tool.[10, 11] (Fig 2)

We continued to use the same concepts outlined by Ravitch for surgical management of pectus excavatum.

Surgical Technique:

With the patient under general (endotracheal) anesthesia, a small longitudinal skin incision 4 to 6 cm in length was made over the deepest part of chest wall deformity. Subcutaneous undermining dissection was then extended to the margins of the depressed deformity. Then subperichondrial resection of the offending pairs of costal cartilages, separation of the perichondrium from the sternal edge, sternal remodeling, and stabilization were done.[12]

However, during this study, this technique was shifted over years to make the procedure less invasive. By developing a limited transverse sub-mammary skin incision with generous subcutaneous flap over the muscle fascia (Fig 3,4). Approximately three to four sets of costal cartilages were removed to get optimal remodeling. The xiphoid process was detached from the sternum.

After cartilages removal and division of the perichondrium from the sternal edge, all patients underwent a sternal table osteotomy. In the first two cases, we followed the standard Ravitch technique by performing a posterior table osteotomy with placement of a triangular wedge of rib bone harvested from one of the ribs lateral to the excised cartilage for stabilization. The small bone wedge (approximately 2-3 cm in length) was harvested through the same incision. Exposure was facilitated with a deep retractor. The harvested bone wedge was held in place with two heavy nonabsorbable sutures.

Later on, the technique was changed, the xiphoid process was detached from the sternum and the procedure became more easier by performing just an anterior wedge osteotomy using the redo sternal saw leaving the posterior table intact, thus allowing easy bending of the lower end of the deformed sternum to go ventrally so that correcting the deformity.

Final stabilization was done using Kirshner wires mounted on drill. In all cases we used two long Kirshner wires as a strut passing transversely under the lower segment of the sternum. Beginning from the right side through the anterior bony end of one of the ribs passing transversely under the lower segment of the sternum going to the left passing through anterior bony end of the opposite rib (fig 5). In 3 children we used another one kirshner wire to be passed from downward upwards through the lower segment of the sternum passing through the osteotomy to the upper part of the sternum . That was done while protecting the anterior mediastinum by a metal mallet. These longitudinal wires allowed excellent fixation of the two parts of the sternum in a straight line. Struts were easily removed after 6 to 8 months as an outpatient procedure.

Asymmetry can be easily dealt with by adjusting the angle of the osteotomy. When the right side is most severely depressed, the right side of the osteotomy should be more cranial and the left side more caudal, with the angle roughly approximating the degree of twist. This maneuver changes the axis of elevation so that when the distal sternum is then brought forward and stabilized with a bone wedge, the "twist" in the sternum is straightened out. Flattening of the sternum results in mild lateral deviation to the right. However, once covered with muscle, subcutaneous tissue, and skin, this degree of deviation cannot be noticed and only the flatness of the chest wall is apparent (Fig 6).

Anesthetic Technique:

After induction of general anesthesia, muscle relaxation and initiation of mechanical ventilation (as appropriate to age and body weight), thoracic epidural catheter was placed for postoperative pain control. The epidural catheter was routinely placed preoperatively by the anesthesiologist at the most appropriate level of the dorsal spine, usually T3-T8 level. Epidural catheters were placed using "loss of resistance technique", test-dosed with local anesthesia alone or in combination with fentanyl, and afterward a continuous epidural infusion was maintained. Postoperative pain was assessed by nursing and house staff on the used scale, with adjustments of the dose rate or analgesic medication as appropriate.

Indwelling epidural catheters placed at the time of surgery lead to smooth postoperative course. This strategy has greatly reduced the amount of narcotics required and allowed for more rapid mobilization.

We also reviewed hospital length of stay, complications, immediate patient satisfaction (table I), hospital charges and total direct costs.

Parents were informed of the technique of Ravitch approach and discussion included benefits and relative risks. Data on demographic, surgery related and pain-related variables were collected. Statistical analysis was done using SPSS-9 (Statistical Package

for Social Sciences version program.

RESULTS

This study included fifteen patients who suffered from pectus excavatum and were repaired using Ravitch technique in the period between 2001 and 2006. Nine (60%) were females and six (40%) were males (figure 7). Age distribution at the time of surgery is demonstrated in figure 8.

Figure 9 demonstrated the indication for surgery. In 66.7% of patients the primary indication was psychosocial which lead to interference with social development of the patients and their parents. In 20% of patients chest pain was the primary indication and that was not necessary related to exercise. In the remaining 13.3%, the primary indication was pulmonary compromise, particularly with activity.

The median severity score was 8/10. Asymmetric pectus excavatum was noticed in 33.3% of patients. The right sided subgroup was 80% (4 patients) and only one patient was asymmetric to the left.

The mean age of all patients was 10.6 ± 2.7 years with a mean weight of 30.1 ± 8.5 kg. Thoracic epidural insertion was attempted on 86.6% of patients (13/15), and was effective (used for ≥12 hours postoperatively) in 60% (9/15). Epidural failure was caused by insertion failure (75%; 3/4) or by downstream occlusion (25%; 1/4). These patients were managed with CIOA [4]. Two patients received CIOA (13.4%; 2/15) due to epidural refusal. There was no difference between CIOA [6] and TEA [9] groups with respect to demographics and pain-related variables (table II).

All patients had extubation before leaving the operating room and were sent to the thoracic surgery ward after leaving the recovery room. The average duration of the epidural was 52.5±6.3 hours (range, 36 to 66 hours). Patients received their test epidural dose preoperatively. Thirteen epidurals were initially dosed with bupivicaine (1 to 2 mg/kg) alone or in combination with fentanyl (1 to 2 micrograms / kg). Nine of 13 patients received fentanyl (1 microgram / kg / h) with bupivicaine (0.5 to 1.0 mg / kg / h) in the epidural as their maintenance medication. Five of 13 patients required additional intermittent supplemental narcotics, with an average of two doses of intravenous morphine per day (0.1 mg/kg) over the first 3 postoperative days. In contrast, the six patients who did not have an epidural catheter for pain control required high-dose intravenous morphine (0.1 mg/kg) every 3 to 4 hours, in addition to their maintenance morphine medication, for the first 3 to 4 postoperative days. No catheter-related complications occurred.

Both regimens provided effective analgesia, but better pain relief was obtained in children receiving the epidural (fentanyl / bupivacaine) regimen. Sedation, pruritus, vomiting, and administration of antiemetics were seen in both treatment groups, and even though both the incidence and severity of side effects tended to be higher in children receiving CIOA, no statistically significant difference was found. No episodes of respiratory depression or motor blockade were noticed.

Length of hospital stay and hospital cost were also reported to be compared with similar reports published using new technique for management of such deformity as Nuss procedure. The mean postoperative hospital stay was 3.9 days, for strut removal it was considered as a day case procedure with no hospital stay and the mean total costs was about 1800LE.

Patient Satisfaction

All patients in the series were followed by phone and repeated visits. Fourteen of 15 (93.3%) patients responded to the patient satisfaction survey. Patients were asked to evaluate the results from a low score of 1 to a high score of 5 (Table I).The mean score was 4.2. Distribution of the assessment is shown in Figure 10. Overall, 78.6% of patients rated their own result very good to excellent (Considering that outcome score more than 4 of 5 very good or excellent)

Complications:

Neither operative mortality nor significant intra-operative morbidities were reported. Blood loss was minimal and only three patients needed minimal packed cell transfusion. Two children developed some sort of abdominal distension due to ileus which was managed by stopping oral feeding for one day and resuming it after removal of chest drains. One patient (6%) had a wound infection that required incision and drainage.

Seromas developed after discharge in two patients (13.3%), requiring aspiration. Those patients had transverse submammary incision. We believe that seromas were related to larger flaps that attended the smaller skin incisions. Now, Jackson-Pratt drains are left until drainage fully ceases. If the drainage persists for more than 3 days, we discharge the patient with the drains to be removed in the office. Early results suggest this procedure may reduce the problem.

Another complication, 2 patients returned with pain due to protrusion of one of the transverse Kirchner wires subcutaneously, which needed removal of the wire under local anesthesia before 7 months. One patient developed keloid malformation, which made the patient unsatisfactory with the results although there was no apparent sternal deformity.

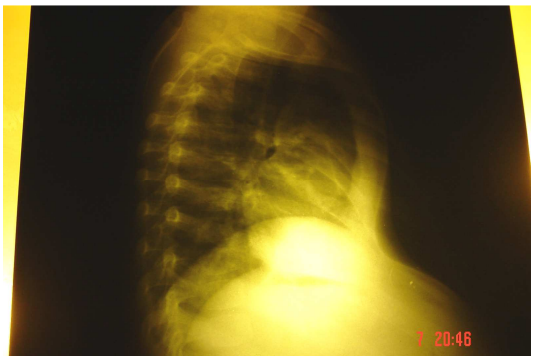

Fig 1: Showing the severity of deformity in plain x-ray chest (lateral view).

Fig 2: CT chest of the same patient.

Fig 3: A limited transverse submammary skin incision.

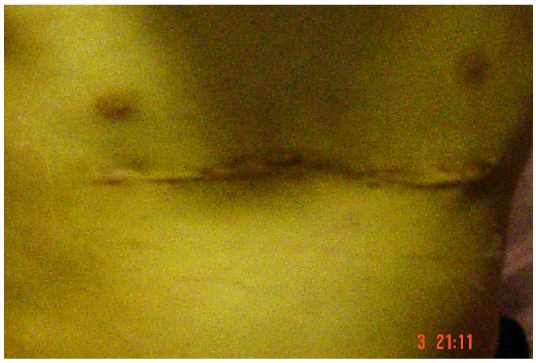

Fig 4: Appearance of scar 3 weeks after repair of pectus excavatum.

Fig 5: Showing the transverse struts.

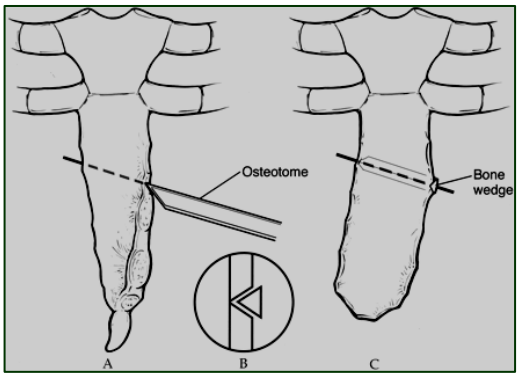

Fig 6: Use of oblique osteotomy to compensate for sternal asymmetry.
(A) Before, showing sternal twist.
(B) Bone wedge to hold anterior position.
(C) After, showing anterior displacement of sternum and elimination of the twist.

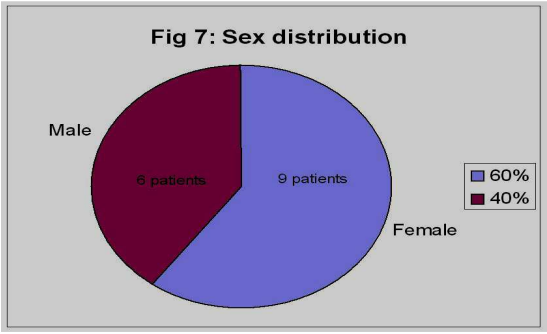

Fig7: Sex distribution of patients subjected to repair.

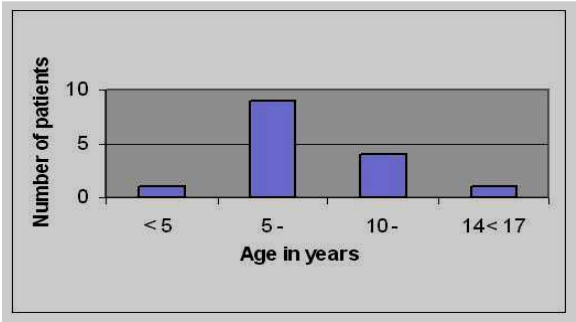

Fig 8: Age distribution of patients at time of repair.

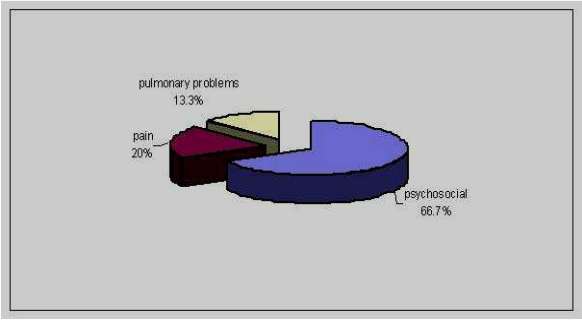

Fig 9: Pie chart of indications of surgery (repair) in pectus excavatum patients.

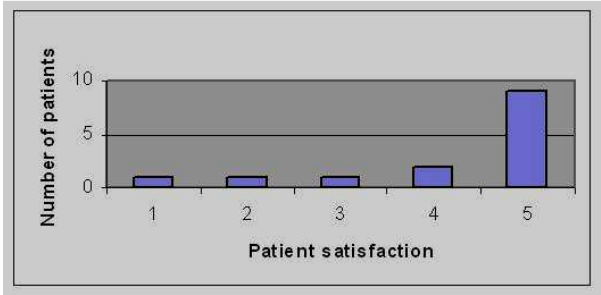

Fig 10: Patient satisfaction scores for fourteen responders.

Table I: Descriptors for the Rating Scale on the Patient Satisfaction Survey

5	I am completely satisfied with my repair
4	I am very pleased with my repair, and notice considerable improvement
3	The repair is just OK
2	I am somewhat disappointed with the result—it doesn't look that great
1	I am very disappointed and dissatisfied with the result

Table II: Pain related variables in both groups

Variables	CIOA (N=6)	TEA (N=9)
Maximum pain score (0–10, first 8 hours post-op)†*	6 [2–8]	4 [2–8]
Time to ambulation (hours) *	52.1 ± 16.2	58.9 ± 31.5
Length of hospital stay (days) *	4.5 ± 1.3	4.6 ± 1.3
Satisfaction score at discharge (1–5)‡	8.5 [7–10]	8 [3–10]
Oxygen therapy: a) Received oxygen*	100%	100%
b) Duration (hours) *	24.1 ± 12.5	25.4 ± 15.9
Duration of opioid administration (hours) *	48.4 ± 14.9	52.5 ± 20.6
Side effects: a) Pruritus	16.6% (1)	22.2 (2)
b) Vomiting	33.2% (2)	33.3% (3)
c) Respiratory depression#	0%	0%
d) Post-op. urinary retention	33.2% (2)	44.4% (4)

† = mean ± standard deviation (number of subjects); ‡ = median [range] (number of subjects)
* = after discharge from Post-Anesthetic Care Unit
# = respiratory rate <12 BPM for age >10 years, or <14 BPM for age 2–10 years

DISCUSSION

Pectus excavatum (PE) is the most common chest wall deformity referred for surgical correction. As a congenital lesion, it is a highly visible anomaly and is easily diagnosed. Its anatomic severity can be readily assessed by visual measurement.[2] As there is continuing development of different modalities of treatment of pectus deformity in different centers, comparisons are difficult and further conclusions are not easy. Since 1950, costal cartilage resection and sternal osteotomy, combined with a variety of internal fixations, have been widely used as the procedure of choice in the treatment of PE.[3] This standard procedure was considered long and complex, with considerable blood loss, a considerable complication rate, and a nontrivial failure rate of 5% to 36%.[3,4] In 1997 a minimally invasive technique for pectus excavatum repair was introduced by Donald Nuss.[6,13]

However because evidence is conflicting concerning the pathophysiology of the deformity, consensus has never been reached about the indications for surgery and still there is unclear sharp indication to overweight a specific procedure. Even there is difficulty in scientifically evaluating the outcomes after surgery.

In this study, we tried to follow the same principle of Ravitch with some modifications to avoid or minimize the previously reported drawbacks of this technique and make the procedure more easy and safe.

The original Ravitch's technique was associated with the fairly radical nature of the operation, which consisted of an extensive anterior chest wall exposure, creation of muscle and skin flaps, extensive cartilage resection, and sternal osteotomy. However, the latest methods for surgical correction of PE are based on the principle that the sternum is an innocent bystander and that the real culprit is the deformed overgrowth of costal cartilages.[2,4] Moreover, the experience with the Nuss technique[6] or the minimally invasive repair of pectus excavatum, has shown that the chest wall deformity, being quite malleable, can be corrected by a convex steel bar without sternal osteotomy and cartilage resection. Besides, Haller and colleagues[10] further reported the possibility of the development of so-called acquired Jeune's syndrome after too-extensive and too-early operations for PE.[14] These considerations provided the rationale for a novel less invasive operation. So, in this work, we did only limited resections of abnormal cartilages through a small transverse skin incision with only anterior sternal osteotomy using the oscillating redo sternal saw which is available in all cardiac surgery theaters For the same consideration, Wang and his colleagues did their procedure with little differences.[15] In our center, instead of using the Nuss bars which are expensive, not available in our country and which was reported that it might migrate, and perforate nearby structures;[16-18] we followed the rational of Ravitch technique with some modifications to coupe with era.

We did not consider CT scans as a routine method to quantify the severity of the deformity or the efficacy of the surgery.

The primary reason to avoid CT scanning is that the findings are of no particular value in planning the operation. Although CT scanning does precisely quantitate the degree of pectus, even Haller and coworkers,[10] in their original description stated that the study "simply documents our selection bias." No actual pathophysiologic consequences have been attached to specific Haller indices, nor have they correlated with the degree of psychosocial impairment that can occur with the deformity.

Recent concern about the potential long-term effects of the radiation from CT scanning in children, including cancer, has also colored our thinking. Therefore, we considered that routine use of the Haller index as an indication for surgery gives no real information about medical necessity, and only adds significant cost and a possible risk that we cannot justify that was also stated by others.[11] The downside of this approach is that we are limited to a less scientific assessment of the degree of severity.

Assessment of the outcome of surgery is also a challenge with the pectus deformity. Because self-image is a major concern in many patients, we thought it was important to find a mechanism to assess how they felt about the outcome, not their surgeon.

The results of the patient survey indicated that patients were satisfied with the results. We are encouraged that more than 4 of 5 considered their outcome very good or excellent. Three patients were dissatisfied with their result. One was the patient with the infection. The other 2 had recurrences, although one recurrence was mild. It is too early in the development of the Nuss procedure to make comparisons about recurrence rates, because most of the Nuss bars have yet to be removed and the cartilage remains. Assessing whether recurrence will be a problem will take years after the bar is removed.

Comparison of the two approaches regarding length of hospital stay is problematic. Current information published on the Nuss procedure report postoperative lengths of stay from 3.7 days to 5.5 days.[6,19] We recognize that these series included earlier data and that, with experience, lengths of stay may diminish. Nonetheless, it must be remembered that these lengths of stay are for the first stage only. Because comprehensive reports are not yet available on the second stage (bar removal), calculating the total length of stay for this approach is not possible. Our mean postoperative length of stay for the

excavatum subset was 3.9 days. The 23% of patients who had a pectus strut removed as part of the repair underwent that part of the procedure as an outpatient and none required hospitalization; therefore the length of stay for the entire event remains at 3.9 days.

Comparison of morbidity rates reported is also difficult. Learning curve, which may explain the higher morbidities should be considered. In the most recent large series, Nuss[17] reported on 303 patients; morbidities listed include a 2.1% wound infection rate, 2.4% rate of pericarditis (2 patients requiring drainage), and an 8.8% rate of bar shifting requiring repositioning.

In this small retrospective series, CIOA and TEA were equally effective in relieving pain in patients who had undergone the Ravitch technique for repair of pectus excavatum. A trend to better pain outcome was observed in the TEA group. The high initial failure rate of TEA in this group was concerning. A larger prospective study evaluating optimal pain management after pectus repair is required.

Thoracic epidural analgesia was completely successful in nine (60%) children who underwent repair of pectus deformity, and effectively reduced the intravenous narcotic demand. Pain control was excellent, and no catheter-related complications were encountered. The data show that this method of analgesia in children is a safe and attractive alternative to intravenous narcotics, and eliminates the potential disadvantages of sedation and respiratory compromise.

Comparing the reported financial data on the Nuss procedure with the technique we use documented significant difference. However, the longer length of stay for the first stage as well as the higher cost of the required supplies suggests that the charges and costs are likely to be higher. In addition, to compare the two approaches fairly, the cost must be evaluated for the entire therapeutic intervention. Because only 23% of the bars as described by Nuss have actually been removed and 100% of these patients will presumably require bar removal, the total cost, length of stay, and complication rate for the completed repair will need to be accounted for in the final analysis[17,20]. With the recent trends toward utilization of lateral stabilizing bars and other methods to prevent loss of bar position, as well as the use of two bars for more complex cases, it remains to be seen what resources will be necessary for their removal and how many patients will require hospitalization after bar removal.

These data support the conclusion that the Ravitch procedure remains a safe and effective approach to the repair of the pectus deformity in all of its presentations. Technical modifications that limit the size of the incision and allow the surgeon the flexibility of dealing with all types of severity and obliquity contribute to consistent outcomes.

A low morbidity with excellent short- and long-term results combined with a high level of patient satisfaction were achieved and should be the standard against which the Nuss procedure is compared.

The ultimate role of the Nuss procedure will be based on the scientific comparison of safety, efficacy, and resource utilization for the two approaches. The Nuss procedure offers repair of the deformity without an anterior scar, but questions remain as to whether that advantage warrants changing the current standard of care. The Ravitch approach offers proven results over a long period of time, but requires a small anterior scar. It is likely that the Nuss procedure will emerge as a useful technique in the armamentarium of the surgeon dealing with certain subsets of patients with pectus excavatum. These updated data from the Ravitch approach should form a useful basis for comparison to make that determination.[9]

REFERENCES

1. Castile R, Staats B, Westbrook P. Symptomatic pectus deformities of the chest. Am Rev Respir Dis 1982; 126: 564-8.
2. Robicsek F. Surgical treatment of pectus excavatum. Chest Surg Clin North Am 2000; 19: 277-96.
3. Ravitch MM. The operative treatment of pectus excavatum Ann Surg 1949; 129: 429-44.
4. Robicsek F, Fokin A. Surgical correction of pectus excavatum and carinatum. J Cardiovasc Surg 1999; 40: 725-31.
5. Haller JA, Scherer LR, Turner CS, Colombani PM. Evolving management of pectus excavatum based on a single institutional experience of 664 patients. Ann Surg 1989; 209: 578-83.
6. Nuss D, Kelly RE, Croitoru DP, Katz ME. A 10-year review of a minimally invasive technique for the correction of pectus excavatum. J Pediatr Surg 1998; 33: 545-52.
7. Rangamani K, Nao Nakatsuka, Montgomery JC. Epidural analgesia versus intravenous opioids after pectus excavatum repair. Canad J Anesth 2004; 51: A93.
8. Fernanda Barros. Continuous thoracic epidural analgesia with 0.2% ropivacaine for pectus excavatum repair in children. Ped Anesth 2004; 14: 192-4.
9. Davis JT, Weinstein S. Repair of the pectus deformity: Results of the Ravitch approach in the current era. Ann Thorac Surg 2004; 78: 421-6.
10. Haller JA, Kramer SS, Lietman SA. Use of CT scans in selection of patients for pectus excavatum surgery: a preliminary report. J Pediatr Surg 1987; 22: 904-6.
11. Frush DP, Donnelly LF, Rosen NS. Computed tomography and radiation risks: what pediatric

health care providers should know. Pediatrics 2003; 112: 951-7.
12. Robicsek F. Surgical treatment of pectus excavatum. Chest Surg Clin North Am 2000; 19: 277-96.
13. Hebra A. Minimally invasive pectus surgery. Chest Surg Clin North Am 2000; 10: 329-39.
14. Haller JA, Colombani PM, Humphries CT, Azizkhan RG, Loughlin GM. Chest wall constriction after too extensive and too early operations for pectus excavatum. Ann Thorac Surg 1996; 61: 1618-25.
15. Wang LS,Tai Kuo K, Wang HW, Yang CH, Chin T. A Novel Surgical Correction Through a Small Transverse Incision for Pectus Excavatum. Ann Thorac Surg 2005; 80: 1951-4.
16. Haller JA. Complication of surgery for pectus excavatum. Chest Surg Clin North Am 2000; 10: 415-26.
17. Nuss D, Croitoru DP, Kelly RE, et al. Review and discussion of the complications of minimally invasive pectus excavatum repair. Eur J Pediatr Surg 2002; 12: 230-4.
18. Moss RL, Albanese CT, Reynolds M. Major complications after minimally invasive repair of pectus excavatum: case reports. J Pediatr Surg 2001; 36: 155-8.
19. Miller KA, Woods RK, Sharp RJ, et al. Minimally invasive repair of pectus excavatum: a single institution's experience. Surgery 2001; 130: 652-9.
20. Croitoru DP, Kelly RE, Goretsky, et al. Experience and modification update for the minimally invasive Nuss technique for pectus excavatum repair in 303 patients. J Pediatr Surg 2002; 37: 437–45